The Lite Version of 12-Lead ECG for Oncology APNs:

Preparation Materials

Brenda K. Shelton, DNP, RN, CCRN, AOCN®

Clinical Nurse Specialist

Sidney Kimmel Comprehensive Cancer Center at Johns Hopkins

Course Objectives

- Review normal ECG waveform configuration
- Outline key features of common dysrhythmias
- Analyze the clinical implications of changes in the 12-lead electrocardiogram in the context of clinical case studies

Overview of Cardiac Diagnostic Tests

ECG (12 lead, stress)	**Pictorial view of conduction pathways**	**Detect ischemia, injury, old infarction, electrolyte disorders, pericardial effusion**
Cardiac enzymes (CPK, Troponin)	Levels of enzymes leaking from myocytes at time of injury	Detection of current acute coronary syndrome.
Echocardiogram	Ultrasound of wall thickness, internal diameter, wall motion, and fluid in pericardial space.	Detects valve, global wall motion, and pericardial fluid abnormalities. Can calculate approximate EF.
MUGA scan	Accurate reflection of circulation of nuclear substance that detects coronary blood flow with/ without exercise. Wall motion abnormalities w/o uptake indicates old infarction.	Detection of significant compromise of coronary blood flow. Helpful to monitor progression of CAD, or recovery from MI.
Brain natriuretic peptide (BNP) serum level	Substance produced by a ventricle in failure. Normal serum < 100 mg/dl, clinically significant if > 300 mg/dl.	Early screening for heart failure, or monitoring response to heart failure treatment

Correct Lead Placement

White is right

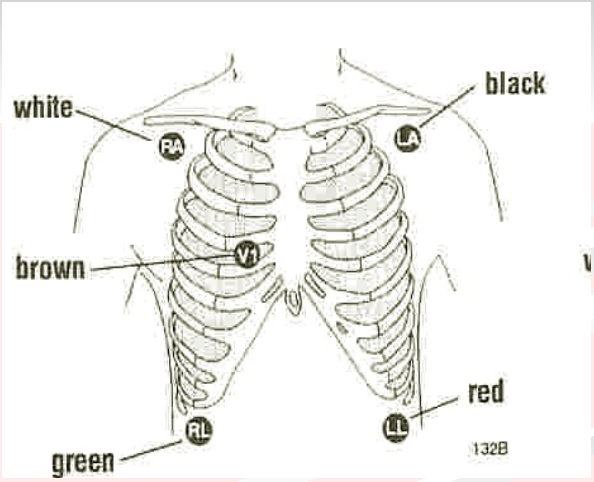

Smoke over fire

Cardiac Action Potentials

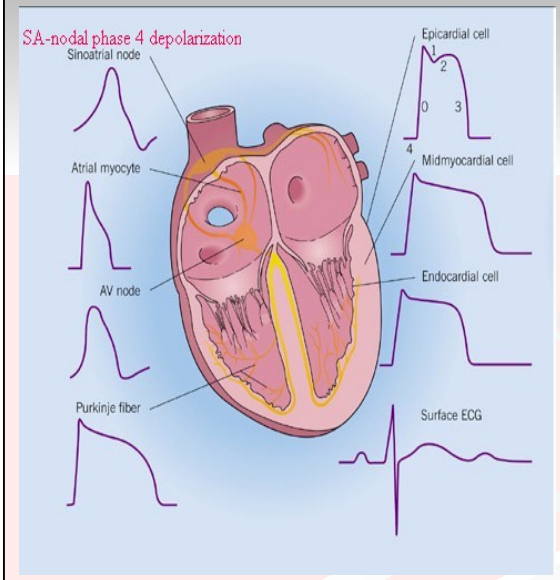

Different areas of the heart have different waves of depolarization, and thus different inherent rates or speed of depolarization and conduction.

ECG Waves = Electrical Conduction

- Normal conduction
- Basic ECG rhythm strip usually reflects view from looking straight at "front of heart"
- Waves created by electrical movement
- Ion movement into cells depolarization = wave
- Ion movement back outside of cell = repolarization
- Electrical movement right arm to left foot = positive wave
- Electrical movement sideways or from lower end of heart upward = negative wave

The Normal Progression of Depolarization

1. P-Wave: SA node to AV node via the left and right atria

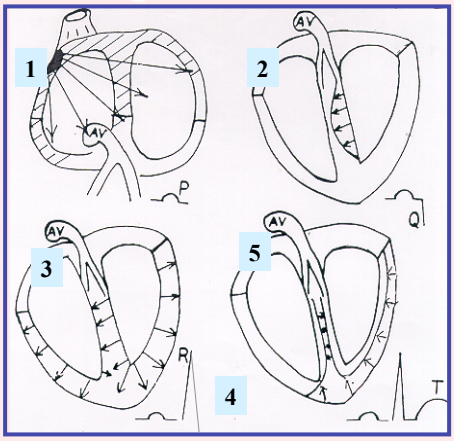

2. Q-Wave (insignificant): Septal depolarization from **left** to **right**

3. R-Wave: Anterior ventricular depolarization

5. T-Wave: Ventricular re-depolarization

4. S-Wave: Posterior ventricular de-depolarization from **bottom upwards**

Components of an EKG

As each area of the heart depolarizes a deflection is recorded by the ECG lead.

The P-wave reflects atrial depolarization (upright)

The QRS reflects ventricular depolarization (and atrial repolarization) (0.04-0.11)

The T-wave reflects ventricular repolarization (same deflection as QRS)

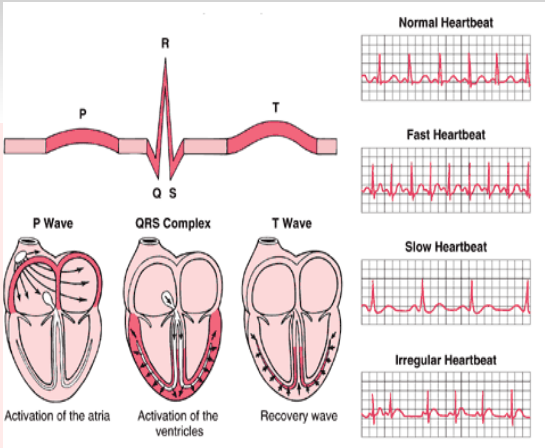

Cardiac Conduction Pathways

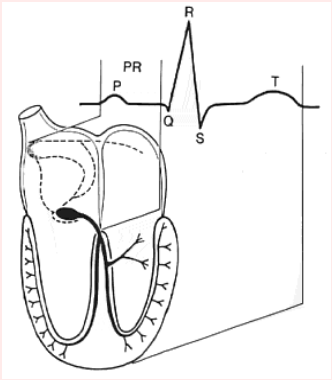

- Intrinsic pacemaker of the heart is the SA node
- Electrical conduction follows an efficient predetermined pathway, reflected as an ECG waveform
- End result of electrical conduction (depolarization) is muscular contraction and blood ejection
- Abnormalities in electrical conduction also affect pumping ability

Classifying Dysrhythmias by Origin

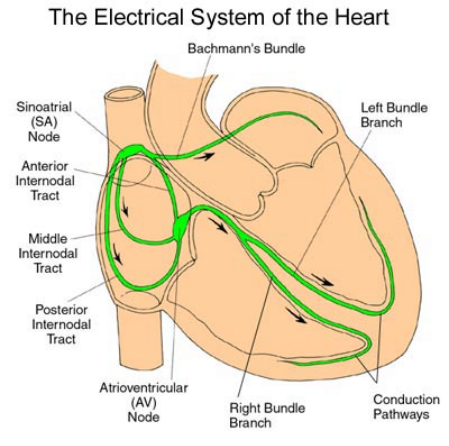

Each type of cardiac tissue has its own inherent rate of conductivity:

- SA node: 60–100
- Atrial tissue: 200–400
- AV node: 40–60
- Ventricular tissue: 20–40

ECGs provide "photograph of electrical activity"

Rhythm Strip

- Basic cardiac rates and rhythms
- Can be measured using 3, 5, or 6 leads
- Usually a single dimensional view
- Best leads for visibility of all waves and measurement of waves/intervals: II, III, V2, V3

12 Lead ECG

- Helpful to detect complex problems with conduction and heart function (e.g., bundle branch blocks, ischemia/ infarction, electrolyte abnormalities)
- Requires placement of 4 limb leads and 6 precordial leads
- Multidimensional: 12 views

Basic Dysrhythmias

Basic knowledge of rhythms should be established before learning 12-lead evaluation

Available on-line resources are easy to find to supplement knowledge and skills

Clinical Effects of Dysrhythmias

- Irregular rhythms, premature beats, or ventricular rates that are too slow or too fast may result in decreased perfusion to vital organs. The organ systems most quickly affected are:
- **Head** – change in mental status or level of consciousness, lightheadedness, vertigo

  Heart – chest pain, hypotension, mottled, diaphoretic, pallor

  Lungs – decreased oxygen sat, increased respiratory rate, shortness of breath, rales, cyanosis

ECG Paper

Height is "muscle mass"- Larger muscle mass = taller waves

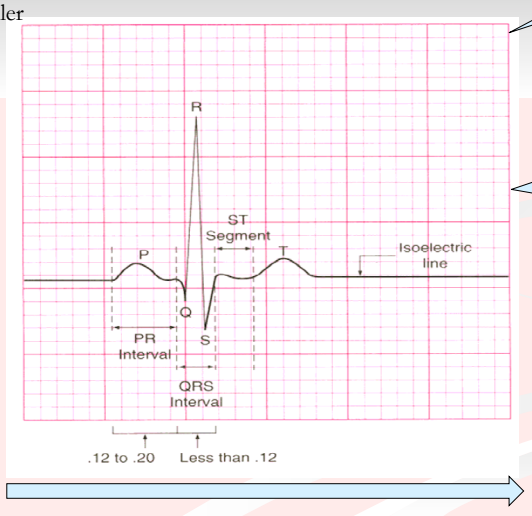

Each small box = 0.04 seconds

Each large box (5 small boxes) = 0.20 seconds

Width is "time"- Wider waves relates to longer time

Rate Calculation

If rhythm is regular:

Divide 300 by the number of large squares between 2 QRS complexes

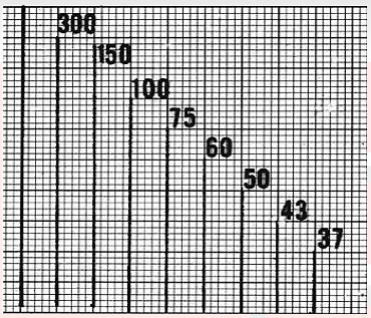

EKG Paper/Rate Calculation

15 blocks = 3 seconds

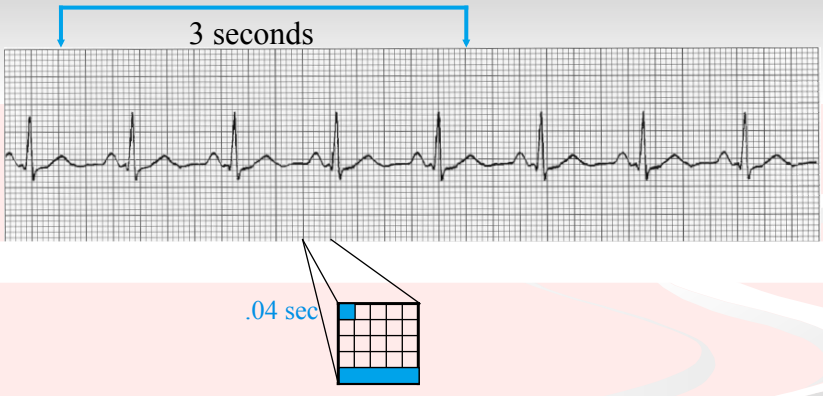

If rhythm is irregular:

Count the number of QRS complexes in 30 large squares (6-second strip) and multiply by 10.

Things to Identify

Is the rhythm fast or slow?

Are there P-waves?

Are there QRS waves?

Are there T-waves?

Is there a P-wave for every QRS?

Is there a QRS for every P?

Do the P – P march out?

Do the R – R march out?

Components of the Complex

- P wave
- P-R interval
- QRS
- Q-T interval
- ST segment
- R-R interval
- T wave
- U wave

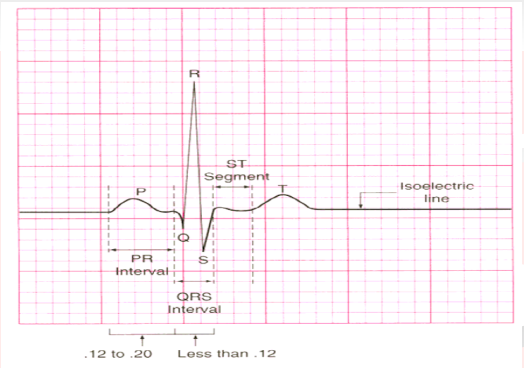

Assessment of the Heart Rhythm

- Calculate the heart rate: count number of complete complexes (P-QRS-T) within the 6-second strip and multiply × 10 (60 seconds). If missing components, count R-waves (ventricular rate) separately from P-waves (atrial rate).
- Assess regularity of R-R interval
- Look for P-waves before EACH QRS. Are they "married to each other"? If intermittently present, mark.
- Assess PR interval in EACH complex, observing for variations in P-waves, or length of interval. Normal is 0.12–0.20 sec [3–5 small boxes].
- Assess QRS interval in several complexes, noting if any are greatly at variance to the routine. Normal is 0.04–0.10 sec [1–2.5 small boxes].
- Determine "key features" abnormality that aids in diagnosis of rhythm.

The "Dipole Concept"

The (+) electrode can be viewed as a movie camera which records electrical activity as coming towards or away from it:

The ECG's positive deflection = An electrical current moving **toward** a positive (+) electrode causes an **upward (+) or positive** deflection on the EKG.

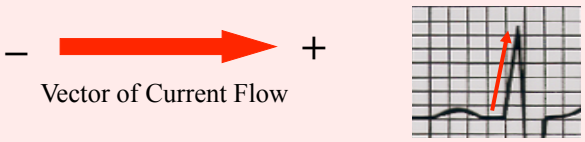

An electrical current moving **away** from a positive (+) electrode causes a **downward (-) or negative** deflection on the EKG.

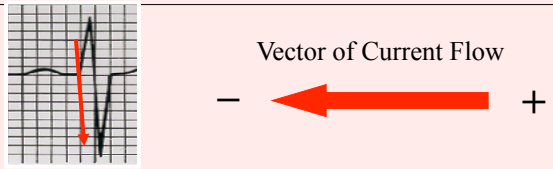

The Isoelectric Form

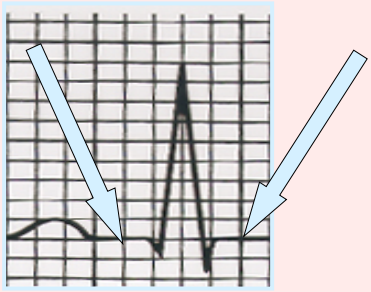

If there is no current detected or if the current is perpendicular to the lead, there will be **no** deflection on the ECG tracing.

Normal Components of an ECG

VOLTAGE in ml VOLTS

(size of muscle mass to pass current through)

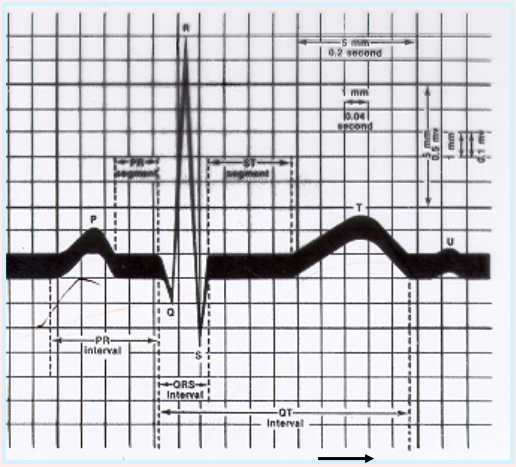

TIME IN SECONDS *(time it takes to move current through the muscle) Each small box = 0.04 sec*

Each ECG wave represents a different area of depolarization in the heart.

Atrial Depolarization
(The P-Wave)

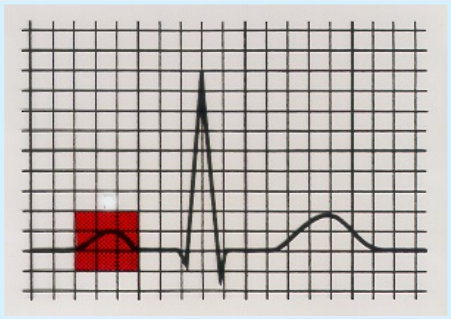

- **CRITERIA FOR A NORMAL P-WAVE:**
- < 2.5 mm tall and < 0.12 seconds wide
- Rounded in contour
- Best visualized in lead II

Ventricular Depolarization (QRS Wave)

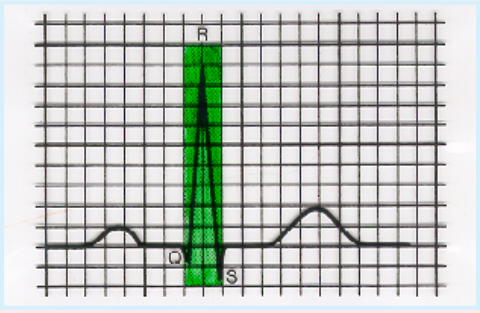

- **Q-wave** is the **first** downward deflection (septal depolarization).
- **R-wave** is the **first** upward deflection.
- **S-wave** is the downward deflection **after the R-wave.**

Ventricular Repolarization:
(T-Wave)

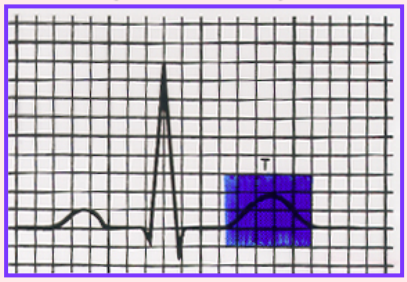

- Repolarization occurs in the opposite direction as depolarization.
- The electrical current begins in the epicardium and moves toward the endocardium.
- Similar to the ST-segment, the **T-wave** is a **sensitive indicator of myocardial oxygen uptake.**

Ventricular Repolarization:
(U-Wave)

- **Usually not seen on a normal ECG**
- **May be intermittent**
- **A sign of delayed repolarization in the purkinje fibers**
- **Check for drug toxicity and electrolyte imbalances (i.e., digitalis toxicity and hypokalemia).**

Atrial Depolarization:
PR Interval

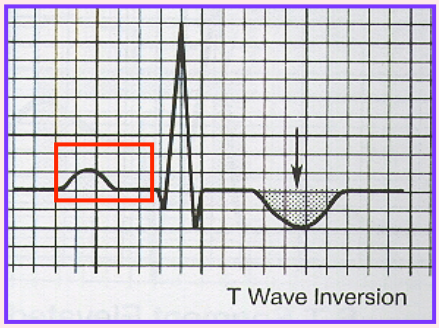

- **Isoelectric period**
- **Time it takes for sinus impulse to travel through AV node to ventricle**
- **Normal = 0.12–0.20 sec**

Waves & Intervals

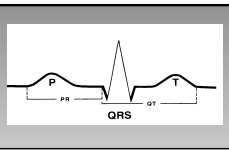

P-Wave	Atrial Depolarization
QRS	Ventricular Depolarization
T-Wave	Ventricular Repolarization
PR Interval	Measures the time it takes for the impulse to travel from the SA node to the AV node 0.12.–0.20 sec (3–5 little boxes)
QRS Interval	Measures the time it takes for the impulse to travel though the ventricles and depolarize 0.04–0.10 sec (1–2½ little boxes)
QT Interval	Measures the time it takes for the ventricles to depolarize and repolarize $\leq$ 0.52 sec

Assessment of the Heart Rhythm

- Calculate the heart rate- count number of complete complexes (P-QRS-T) within the 6-second strip and multiply × 10 (60 seconds). If missing components, count R-waves (ventricular rate) separately from P-waves (atrial rate).
- Assess regularity of R-R interval
- Look for P-waves before EACH QRS. Are they "married to each other"? If intermittently present, mark.
- Assess PR interval in EACH complex, observing for variations in P-waves, or length of interval. Normal is 0.12–0.20 sec [3–5 small boxes].
- Assess QRS interval in several complexes, noting if any are greatly at variance to the routine. Normal is 0.04–0.10 sec [1–2.5 small boxes].
- Determine "key features" abnormality that aids in diagnosis of rhythm.

Overview of Dysrhythmias

Rate abnormality	Sinus rhythms (rate varies)	Normal sinus, sinus bradycardia, sinus tachycardia
P-wave abnormality (atrial depolarization)	Atrial rhythms (rate varies)	Atrial fibrillation, atrial flutter, atrial tachycardia
Displaced location of P-wave/ absent P-wave with normal QRS (junction/nodal transmission)	Junctional/ nodal rhythms (slow rate)	Junctional rhythm, accelerated junctional rhythm
QRS abnormality (ventricular depolarization)	Ventricular rhythms (rate fast or absent)	Ventricular tachycardia, ventricular fibrillation
Abnormal P-QRS relationship; more P-waves than QRS (current transmission between atria and ventricles)	Heart blocks (slow rate)	First degree, second degree type I, second degree type II, third degree

Conduction Disturbances

- **Fluid and electrolyte disturbances**
  - Cisplatin, cetuximab-induced hypomagnesemia
  - Antibiotic-induced hypokalemia
  - Dehydration/fluid overload enhances atrial automaticity
- **Oxygen free radicals**
  - Ara-C
  - Fluoropyrimidines (e.g., 5-FU)
  - Topoisomerase inhibitors
  - Tyrosine kinase inhibitors
  - Cytokines
- **Direct irritation/damage to conduction pathways**
  - Arsenic trioxide
  - Radiation acute and chronic effects
  - Tumor compression of atria
  - Taxanes
  - Esophagectomy, pneumonectomy

Etiologies of Cardiac Rhythm Disturbances

- **Atrial/nodal rhythms**
  - Electrolytes
  - Fluid depletion/ overload
  - Hypoxia
  - Taxanes
  - Radiation exposure
  - Heart block with voriconazole, fluconazole
- **Ventricular rhythms**
  - Hypokalemia/ hypomagnesemia
  - Fluoropyrimidines
  - Arsenic trioxide
  - Cytokines
  - Temazolamide
  - Tyrosine kinase inhibitors

Ventricular Repolarization:
QT Interval

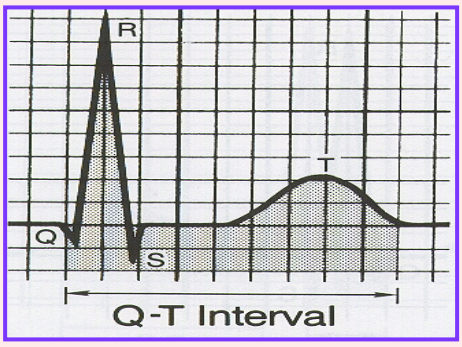

- **The QT interval is rate dependent**
- **It is the total ventricular depolarization and repolarization time**
- **Is normally less than ½ the R-R interval (usually < 0.5 sec)**
- **Measure from beginning of QRS to end of T-wave**
- **QTc is the corrected QT interval based on the pts HR**

QT Prolongation Syndrome

- Prolonged time for myocardial recovery
- Corrected for heart rate = QTc
- Congenital or acquired
- Detection by 12-lead ECG
  - Bradycardia
  - Prolonged QT interval

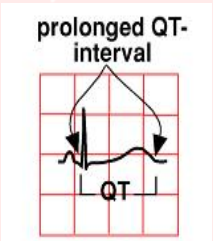

- Highest risk: sudden death from ventricular arrhythmias



Risk Factors for QT Prolongation

- Amphetamines
- Anesthetics: e.g., fluranes, propofol
- Anti-arrhythmic medications: e.g., amiodarone, procainamide
- **Antifungal agents (azoles)**
- **Antidepressants**
- **Antihistamines**
- **Arsenic trioxide**
- Astenizole
- Barium
- Bradycardia
- **Butyrophenomes: e.g., haloperidol, droperidol**
- Caffeine
- Cimetidine
- Decongestants: ephedrine
- Dofetilide
- Dasatinib
- Dyspyramide
- **Electrolyte imbalances: ↓ K+, ↓ Mg++, ↓ calcium**
- **Female**
- **Fluoroquinolones**
- **Histamine receptor antagonists (e.g., ranitidine) and $5HT_3$ antagonists**
- **Metoclopromide and related motility stimulants**
- Macrolide antibiotics
- **Methodone**
- **Ondansetron and related serotonin antagonists**
- Pentamidine
- **Phenothiazines**
- **Proton-pump inhibitors**
- **Selective estrogen receptor modulators**
- Sotalol
- Terfenadine
- Valproic acid

Normal Sinus Rhythm (NSR)

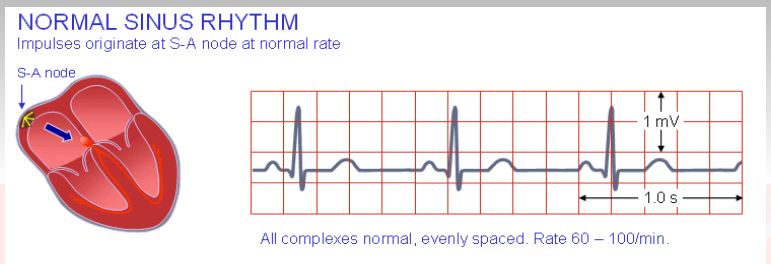

P-wave, QRS complex, and T-wave should all be primarily positive deflections in Leads I – III

P-wave: consistent morphology (shape or configuration), precedes each QRS

PR interval: 0.12–0.20 seconds, isoelectric

QRS: 0.06–0.11 seconds, consistent morphology

T-wave: consistent morphology, same deflection as QRS

Rate: 60–100 bpm

Sinus Bradycardia

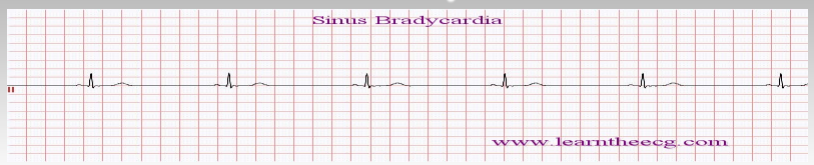

Sinus rhythm with rate less than 60

Patients may or may not tolerate this slow rate

Treated only if patient is exhibiting **serious** signs and symptoms – ID and treat cause, hold medications that are slowing heart rate, administer atropine, dopamine infusion, pacing

Sinus Tachycardia

Sinus rhythm with rate greater than 100

Discernible P- and T-waves

Identify and **treat the cause** if patient is symptomatic

Dehydration	**Pain**
Hypovolemia	**Anxiety**
Fever	**Hyperthyroidism**

Atrial Rhythms

Rhythms that occur due to ectopic or irritable foci arising in one or both atria, or if the SA node fails to fire and the atria take over as the pacemaker.

Premature Atrial Contraction (PAC)

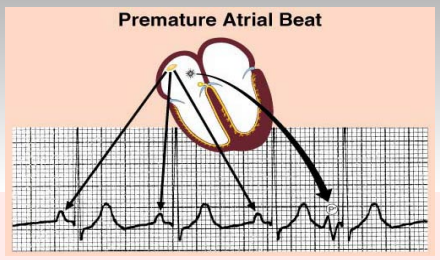

- Early or premature beat from ectopic atrial foci
- P-wave has a different morphology or shape from normal atrial depolarization, it may be biphasic (positive and negative deflection)
- If every other beat is a PAC, this is called atrial bigeminy
- Ventricular response is early
- Etiology: stress, stimulants such as caffeine, nicotine, idiopathic
- Treatment: usually unnecessary, may precede atrial fibrillation

PACs

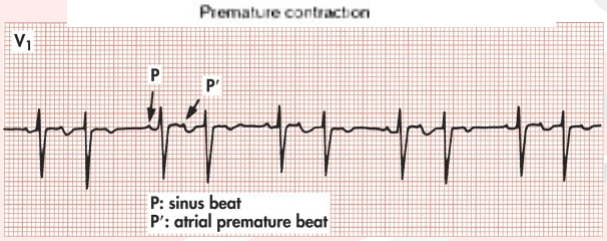

Atrial Flutter

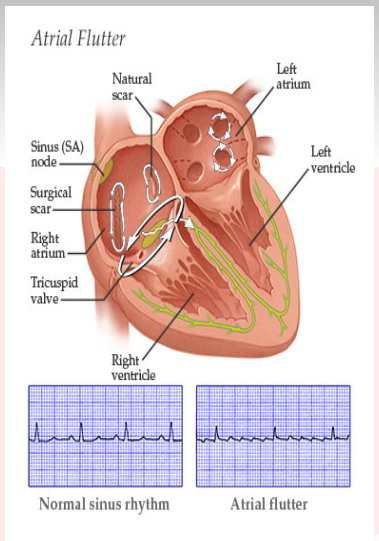

- Single irritable focus in one of the atria with reentry phenomenon.
- P-waves are described as sawtooth or picket fence.
- Ventricular response may be slow or rapid depending on number of P-waves that are conducted or blocked.
- Ventricular rhythm may be regular or irregular.

Atrial Flutter

Often described by number of P or flutter waves necessary to conduct a QRS complex; i.e., atrial flutter with a 3:1 block

May be regular or irregular, rapid or slow ventricular response

P waves described as "picket fence" or "sawtooth"

Treatment – depends on rate and patient symptoms

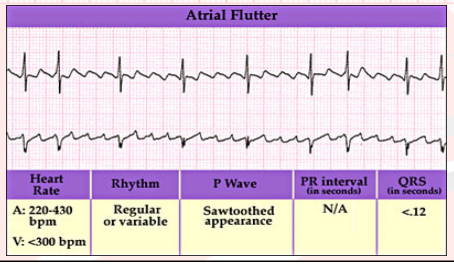

Heart Rate	Rhythm	P Wave	PR interval (in seconds)	QRS (in seconds)
A: 220-430 bpm V: <300 bpm	Regular or variable	Sawtoothed appearance	N/A	<.12

Atrial Flutter

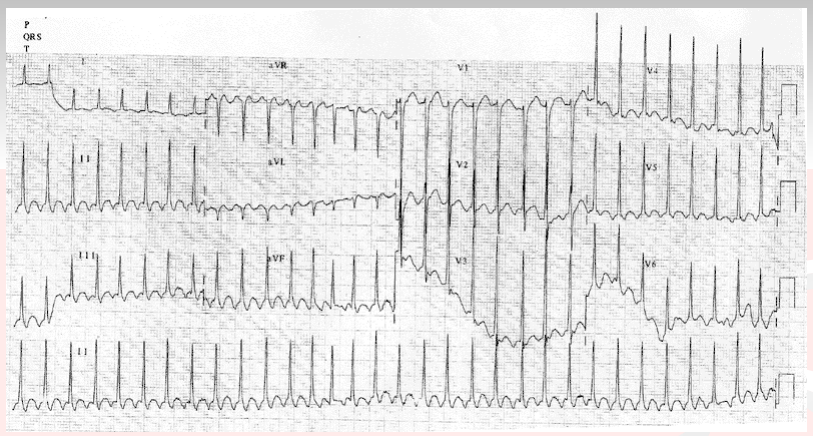

Atrial flutter with rapid ventricular response is a type of SVT (supraventricular tachycardia)

Atrial Fibrillation

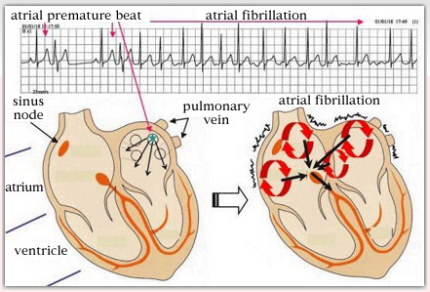

- Several irritable foci in one or both atria
- Ventricular response may slow or rapid
- No defined P-waves but fibrillatory or f-waves
- Ventricular rate is <u>always</u> irregular

Atrial Fibrillation

Atrial fibrillation with slow ventricular response and rapid ventricular response (which is also a type of SVT)

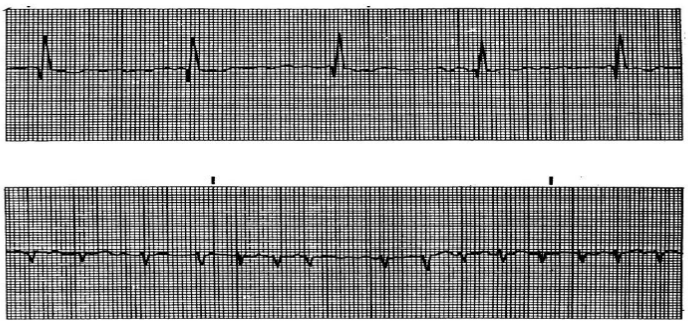

Complications of Atrial Fibrillation

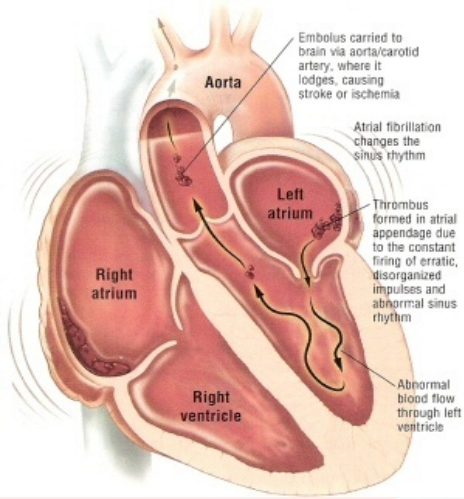

- One serious complication of atrial fibrillation is embolic CVA.
- Less commonly, pulmonary emboli may occur.
- Treatment of atrial fibrillation often includes anticoagulation to prevent thromboemboli formation or placement of IVC filter.

Supraventricular Tachycardias

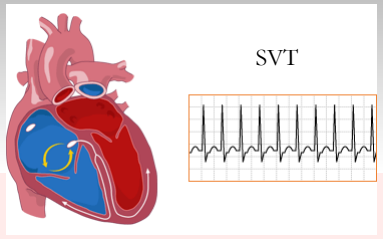

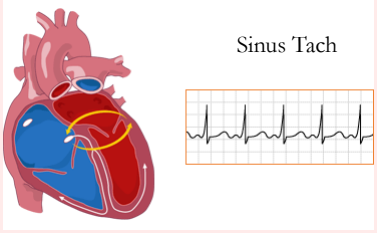

- A group of tachycardias whose origin is an ectopic foci above the ventricles but not from the SA node
- One wave visible between QRS complexes
- May be atrial or junctional
- QRS will be narrow, between 0.08–0.11 seconds, unless a bundle branch block also exists

Supraventricular Tachycardias

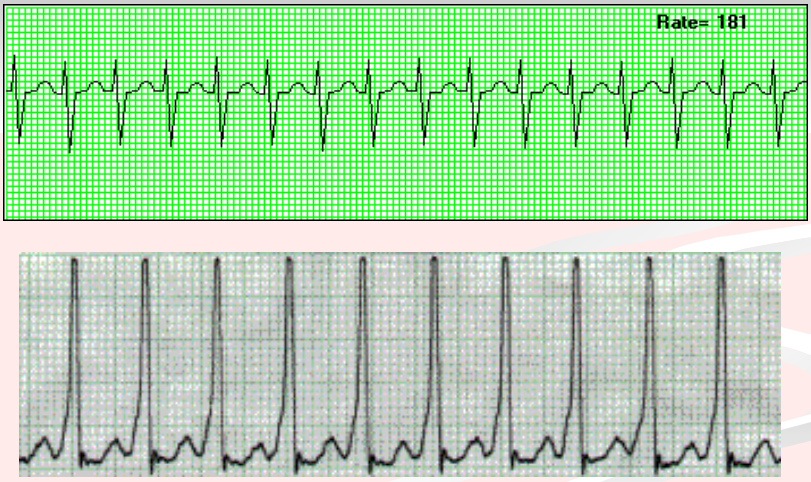

Junctional Rhythms

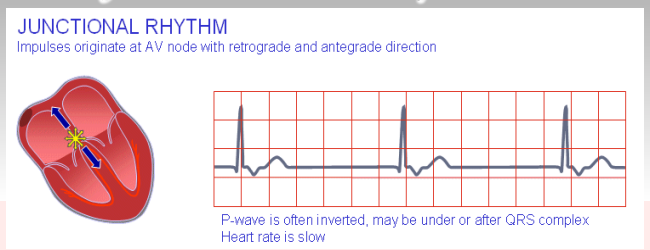

Rhythms that arise from the AV nodal tissue which is located to the right of the septum.

Inherent rate of AV node is 40–60 bpm.

The AV node is innervated by the parasympathetic NS.

The AV node delays transmission of atrial impulses, allowing time for the atria to contract and empty.

Junctional Rhythm or Junctional Escape Rhythm

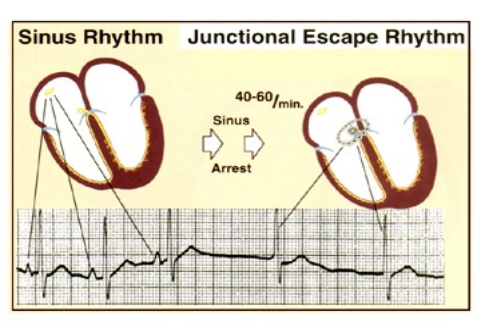

Considered an escape rhythm due to failure of SA node to fire or conduct.

Atria are depolarized by retrograde conduction, therefore P-waves are usually absent, if present, they are inverted or follow the QRS.

Ventricular Rhythms

Rhythms that arise from an ectopic foci in one or both of the ventricles

Premature Ventricular Contractions

Multifocal PVCs – 2 or more morphologies

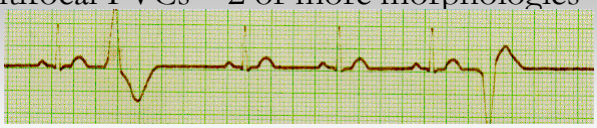

Couplets – 2 consecutive PVCs

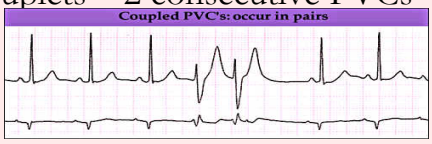

R on T PVC – PVC occurring during relative refractory period of repolarization

Premature Ventricular Contractions

Ventricular Bigeminy

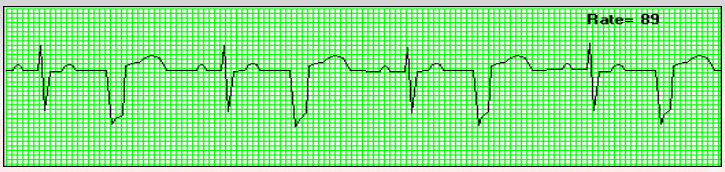

Ventricular Trigeminy

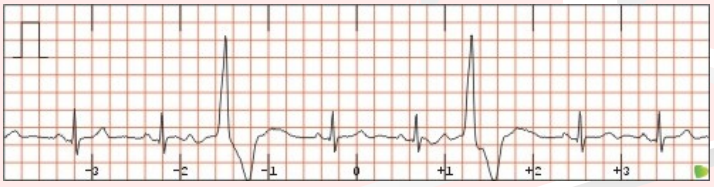

PVCs

Etiologies

- ↓ K+, ↓ magnesium, ↑ calcium
- Hypoxemia, hypercapnia
- Foreign body in heart: catheters, tumor, clot
- Nicotine, caffeine, ETOH, cocaine
- Stress, sleep deprivation
- Myocardial ischemia
- Myocarditis, pericarditis
- Cardiomyopathy
- Myocardial contusion

Idioventricular Rhythm

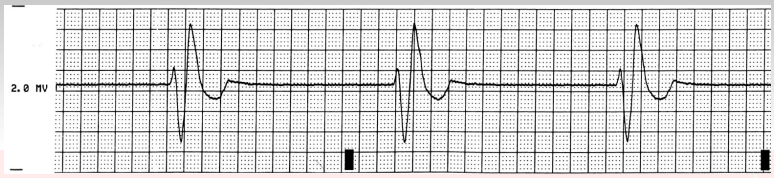

- Also called ventricular escape rhythm.
- Occurs when both the SA and AV nodes fail to fire or conduct, so ventricles contract at own intrinsic rate.
- QRS is always wide, >0.12 seconds, with T-wave in opposite deflection.
- Treatment: Dopamine, epinephrine infusion, pacing

Ventricular Tachycardia (VT)

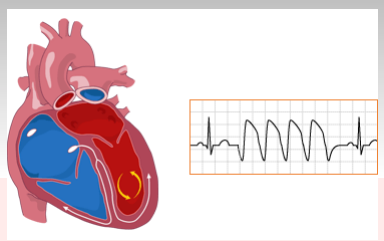

Three or more consecutive PVCs at a rate greater than 100.

Patient may be asymptomatic, symptomatic, or pulseless.

Treatment: Amiodarone or lidocaine if symptomatic but stable, emergency cardioversion if unstable or pulseless

Ventricular Tachycardia

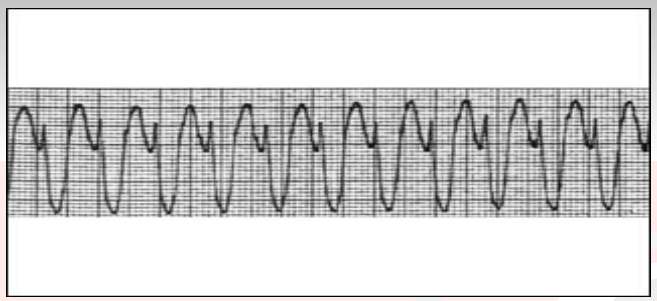

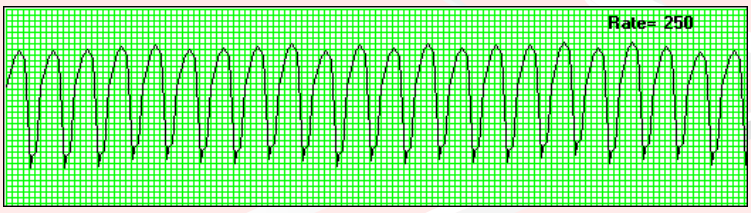

Ventricular Fibrillation (VF)

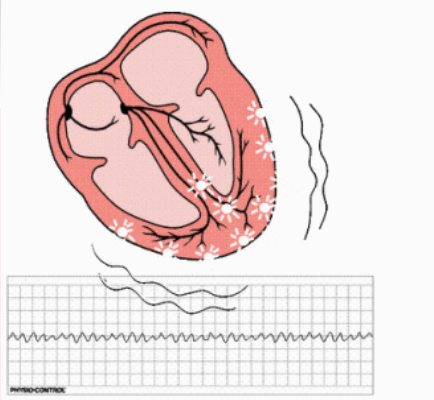

- A chaotic rhythm that produces no cardiac output due to multiple ectopic or irritable foci in the ventricles.
- VF is lethal unless treated immediately with defibrillation.
- CPR, antidysrhythmics such as amiodarone or lidocaine, only enhance defibrillation.

Ventricular Fibrillation

Coarse V Fib

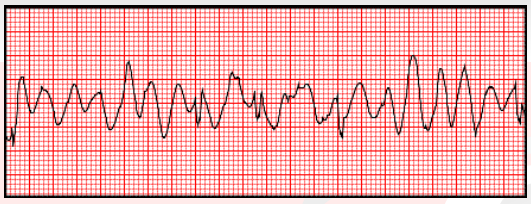

Fine V Fib

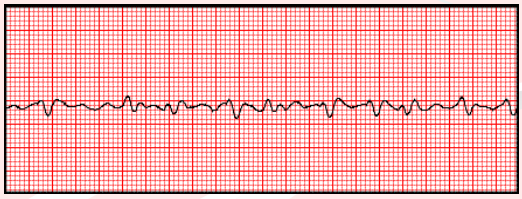

Torsades de Pointe

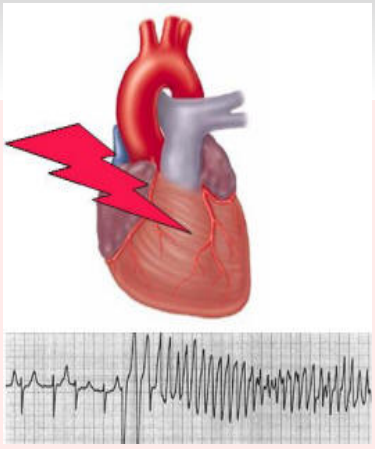

- A type of ventricular tachycardia and should be treated as pulseless rhythm with immediate defibrillation.
- Often caused by antidysrhythmics that prolong QT interval.
- May be caused by hypomagnesium, so administer magnesium sulfate.

Pacemakers

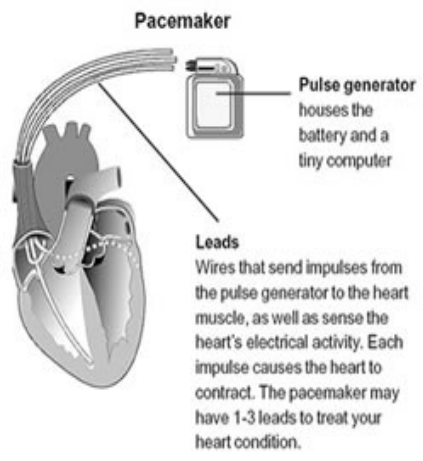

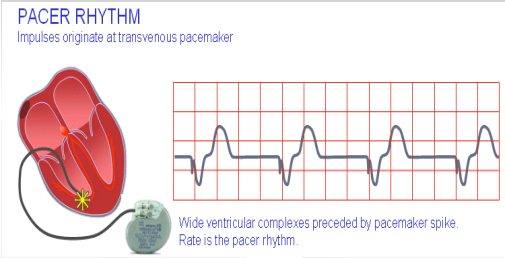

Ventricular Paced Rhythms

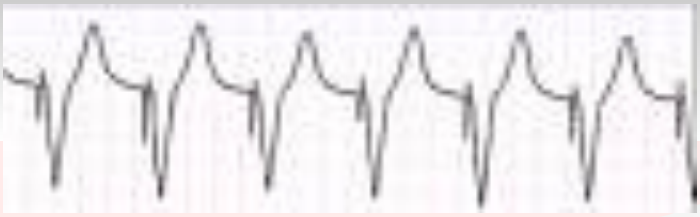

Pacer spike followed by wide QRS complex with a T wave in the opposite deflection. Looks like a PVC because the ventricle is being stimulated by the pacing lead or pad.

AV Sequential Paced Rhythms

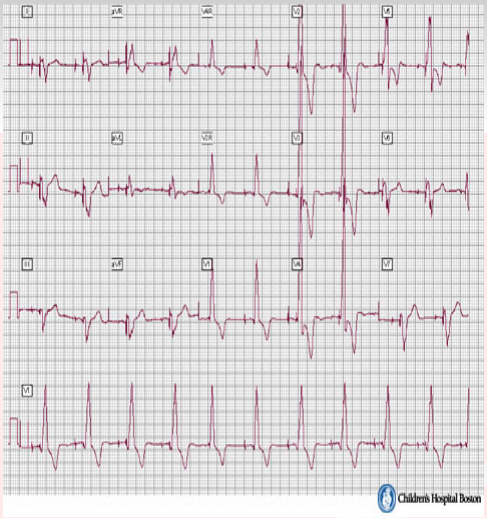

Pacemaker with both atrial and ventricular pacing leads or pads.

Provides atrial contraction, which can increase cardiac output by 25%–30%.

Failure to Sense or Undersensing

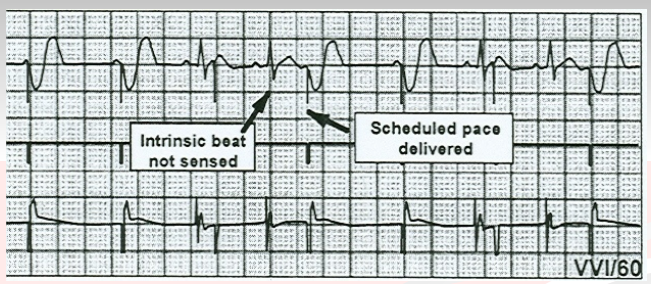

Malfunction in the sensing capacity of the pulse generator. Paced beat could be delivered during refractory period of cardiac cycle potentially causing ventricular fibrillation (R on T phenomenon).

Treatment: Adjust or increase mV or gain of pacemaker

Failure to Capture

Malfunction of pacemaker to produce a QRS complex or wave of ventricular depolarization.

May be due to endocardial or myocardial scar tissue or damage to pacing lead or patch.

Treatment: Increase of mA or energy delivered, replacement of pacing lead or patch

AV Blocks

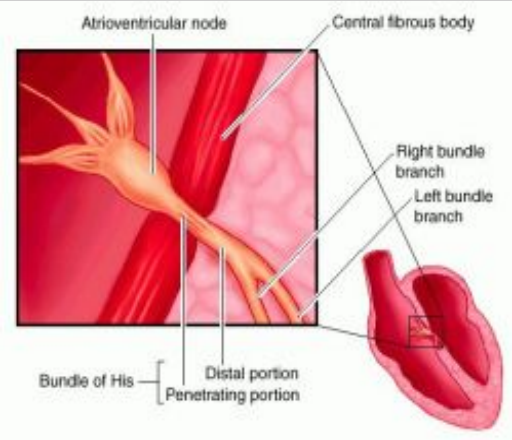

Slowed or blocked conduction in the AV nodal tissue or HIS bundle.

First Degree AV Block

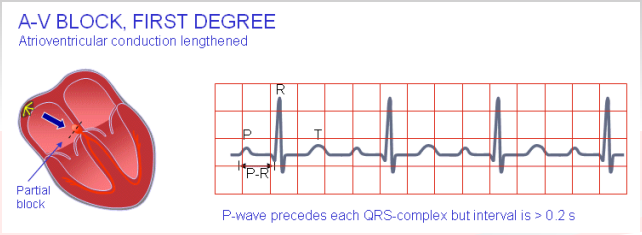

Sinus rhythm criteria except PR interval prolonged greater than 0.20 seconds.

Etiologies: Medications, i.e., digoxin, AV node ischemia

Treatment: Hold medication if suspected cause

Second Degree AV Block: Mobitz Type 1 or Wenckebach

PR interval gets progressively longer until QRS is dropped or not conducted. Rhythm is irregular.

Etiologies: Ischemia of AV node

Treatment: Monitor for progressive block, may require pacemaker

Second Degree AV Block: Mobitz Type 2

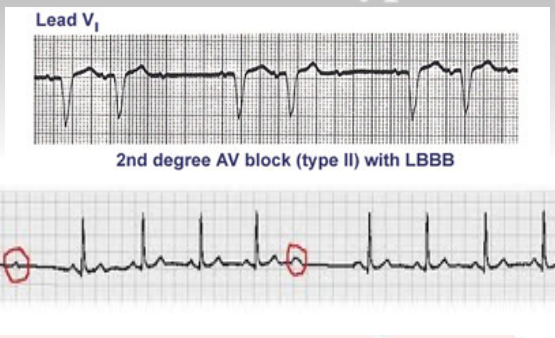

Regular P-P intervals but some P-waves not conducted. Block may occur regularly or sporadically.

Indicative of more serious disease of AV node

Treatment: Monitor for serious signs and symptoms, prepare for possible need for temporary pacemaker

Third Degree AV Block
Complete Heart Block

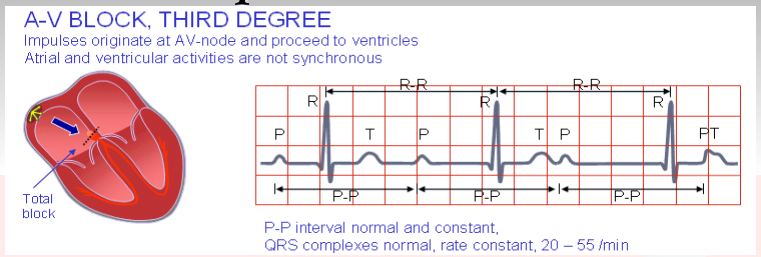

P-P intervals are regular as are R-R intervals, but P-waves are not conducting QRS complexes. Atria and ventricles are dissociated. PR intervals will be variable. QRS complex may be narrow or wide depending level of AV block.

Treatment: Pacemaker at bedside, may test for ability to capture, atropine, dopamine infusion if serious signs and symptoms

Complete Heart Block

If the block is low in the AV node or HIS bundle, the QRS will be prolonged or >0.12 seconds.

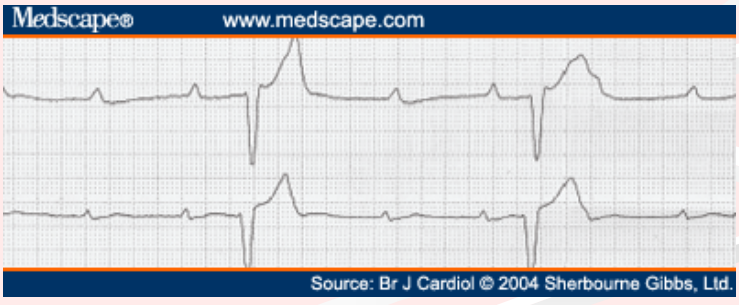

Complete Heart Block

If the block is high in the AV node, the HIS bundle may initiate ventricular depolarization and therefore the QRS will be normal in duration or <0.12 seconds.

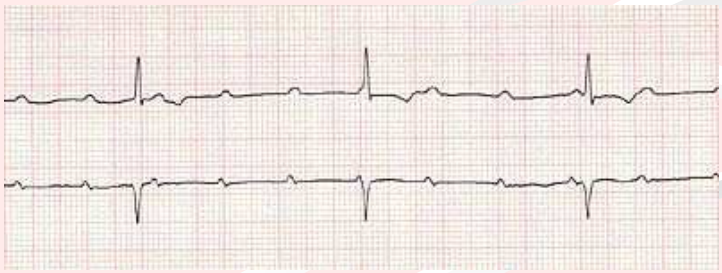

Management of Conduction Disturbances

- Acute
  - Pharmacologic
    - Correct electrolytes (K+ >4.0, Mg++ >2.0)
    - Correct fluid and acid-base imbalances
    - Correct hypoxemia
    - Adenosine
    - Calcium channel blockers
    - Beta-blockers
    - Amiodarone
  - Electrical
    - Emergent cardioversion
    - Temporary transcutaneous pacing
- Chronic
  - Pharmacologic
    - Digoxin
    - Calcium channel blockers
    - Amiodarone
  - Electrical
    - Permanent pacer
    - AICD
  - Interventional
    - Biphasic cardioversion
    - Ablation therapy

Classes of Anti-dysrhythmic Medications

- **I: Local anesthetic properties, interferes with fast Na channel**
  - Ia: depress Na conductance (quinidine, procainamide)
  - Ib: Natural blockade, increase K conductance (lidocaine)
  - Ic: Natural blockade, slow conduction (flecainide)
- **II: Interferes with slow Na channel, decreases automaticity (beta-blockers)**
- **III: Interferes with norepinephrine, increases action potential duration (Bretylium)**
- **IV: Ca antagonist, increases AV nodal refractory period (verapamil)**
- **Unclassified or combination agents (adenosine, amiodarone)**

Diltiazem

- Ideal for conversion of atrial dysrhythmias, not just rate control [as with digoxin or beta-blockers]
- Administration
  - Loading dose: 0.25–0.35 mg/kg (20–25 mg) in PI, but usually ~ 10–15 mg for oncology patients, may repeat × 1
  - Intravenous infusion: 5–20 mg/hr, titrate to effect and lack of adverse effects, infusion half-life 10–20 minutes
  - Traditional or sustained release oral agents: first dose administered as infusion discontinued
- Adverse effects: hypotension, bradycardia, hypoxemia, nausea

Adenosine

- Nucleoside analog of adenosine triphosphate
- Creates a "chemical defibrillation"
- Indications: SVT, to slow heart rate for diagnostic purposes (A Fib, A Flutter, VT)
- Administration:
  - 6 mg, then 12 mg, may repeat additional 12 mg
  - Rapid IV push
  - As central as possible
  - Maintain continuous ECG monitoring and printing during administration
- Adverse effects (*short-lived* [due to half-life 1–6 sec]): headache, dizziness, chest pain, dyspnea

Amiodarone

- Anti-dysrhymic agent with mixed clinical actions.
- Indications: tachycardia (any origin), intrinsic atrial rhythms, ventricular ectopy
- Administration:
  - IV bolus 150 mg diluted in 50–150 mL over 10 minutes
  - Initial infusion 1 mg/min for 6 hours
  - Maintenance infusion rate 0.5 mg/min for 18 hours
  - IV administration most stable in dextrose 5%, glass bottles (stat doses ok in normal saline or plastic)
  - Switch to PO after 24 hours
  - May administer several 150 mg boluses during a 24-hour period for break-through dysrhythmias until maximum dose of 2.0 grams
- Adverse effects: hypotension, bradycardia, nausea, vomiting, peripheral neuropathy, pulmonary fibrosis (high dose or prolonged therapy), hepatic transaminase elevations, corneal microdeposits, photosensitivity, hypothyroidism

12-Lead ECG: Conceptual Tenants

- Core concepts of "multilead ECGs"
  - Taking pictures of heart's conduction from multiple angles
  - Each lead represents a different "view"
  - Each lead is oriented to a section of the heart
- What information is provided through its evaluation
  - Anatomical orientation of the heart
  - Size of the chambers
  - Disturbance of conduction
  - Ischemia, injury or infarction
  - Electrolyte imbalance
  - Drug toxicity/therapy
- Process of evaluation
  - Assess ECG rhythm via rate, regularity, PR, QRS, QT
  - Assess other medical/ cardiac problems through analysis of the 12 leads
  - Review each lead for the defined parameters
  - Check for upright waveforms in all except AVR where ALL waveforms are inverted. If AVR is not inverted check lead placement. Note inverted waves and lead locations.
  - Check R wave progression in precordial (chest) leads
  - Assess each lead for significant Q-waves, ST elevation or depression, T- wave inversion

Precordial Leads

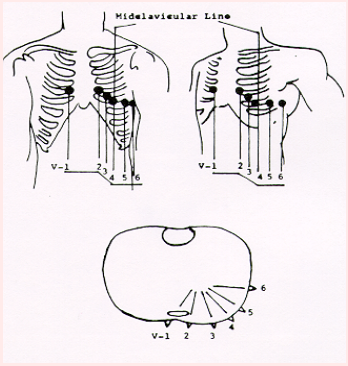

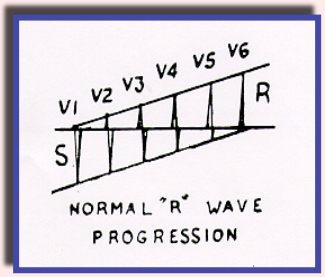

- V1 and V2: Right-sided or Septal Leads
- V3 and V4: Transitional Leads
- V5 and V6: Left-sided or Lateral Leads

Precordial Leads:
R-Wave Progression

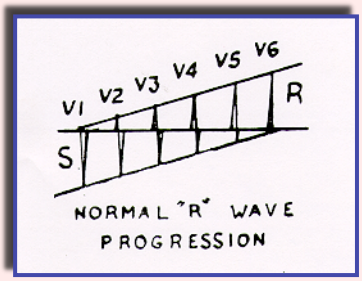

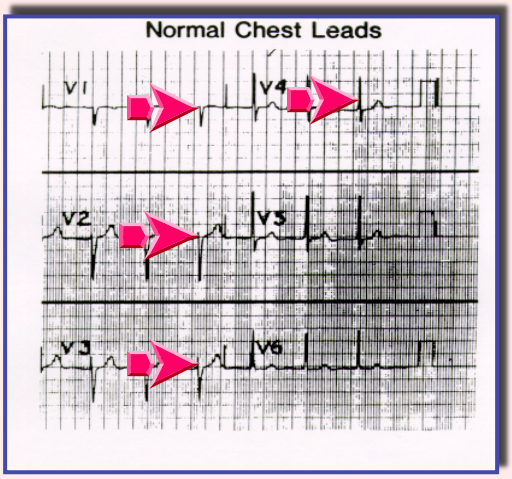

Coronary Artery Disease

- **Risk factors**
  - Older age
  - Chest irradiation including the heart
  - Heavily treated with alkylating agents
  - Long-term corticosteroids
  - Progranulocytic leukemia
  - Link between cancers and CV disease
  - Higher incidence of acute myocardial infarction with certain malignancies
  - Einhorn regimen for testicular cancer
  - Bevaizumab
- **Onset as early as 2 years after exposure**
- **Peak incidence 10 years after exposure**

Myocardial Infarction

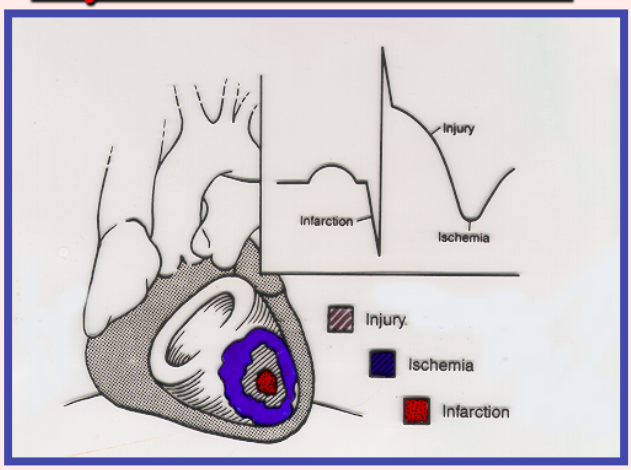

Three ways the myocardial tissue is affected:

Significant Q-Waves

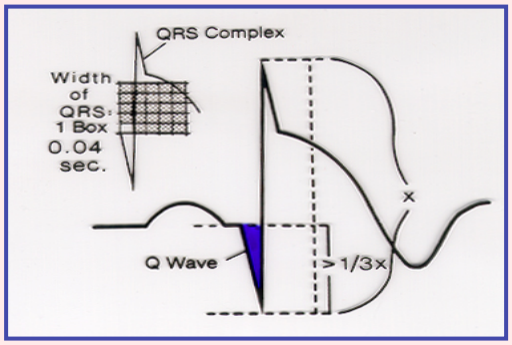

A SIGNIFICANT Q-wave should be:

1. One-third the height of QRS complex
2. 0.04 second (1 small box wide) in duration
3. Must be present in 2 related leads

More on Q-Waves….

1. Q-waves are not significant if seen in one lead.
2. Q-waves are never significant in AVR.
3. Q-waves in V1 alone are ignored.
4. Q-waves in III alone are ignored.

Ventricular Repolarization

ST Segment

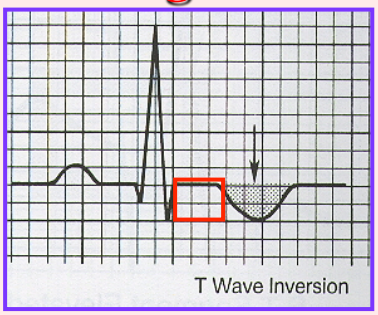

- **The ST-segment is normally isoelectric**
- **Sensitive indicator of myocardial oxygenation**
- **May be elevated or depressed secondary to variations in MVO_2**

Ventricular Repolarization
(J Point)

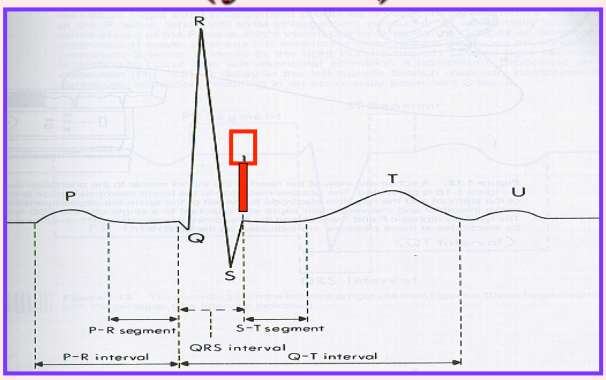

- **Point at which the QRS wave meets the isoelectric baseline**
- **Used as a reference point in determining ST changes**
- **Measure the elevation or depression 0.04 to 0.08 seconds after the J point**

12-Lead ECG Variations in AMI and Angina

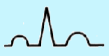
Baseline

Ischemia—tall or inverted T-wave (infarct), ST segment may be depressed (angina)

Injury—elevated ST segment, T-wave may invert

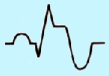
Infarction (acute)—abnormal Q-wave, ST segment may be elevated and T-wave may be inverted

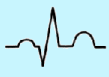
Infarction (age unknown)—abnormal Q-wave, ST segment and T-wave returned to normal

AMI Localization

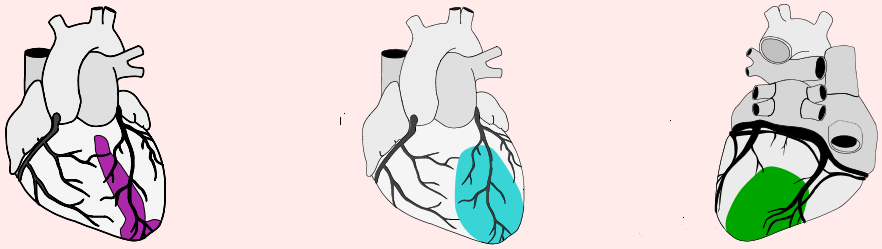

I lateral	aVR	V_1 septal	V_4 anterior
II inferior	aVL lateral	V_2 septal	V_5 lateral
III inferior	aVF inferior	V_3 anterior	V_6 lateral

Recognition of AMI

- Know what to look for:
  - ST elevation >1 mm
  - 3 contiguous leads
- Know where to look
  - Refer to *2005 ECC Handbook*

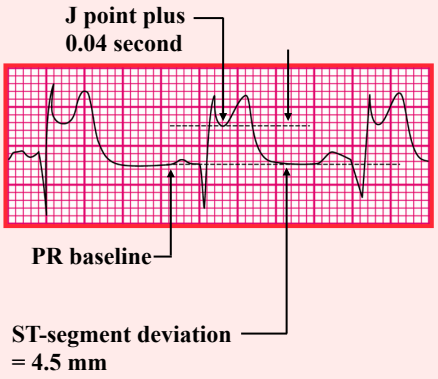

How to Measure ST-Segment Deviation

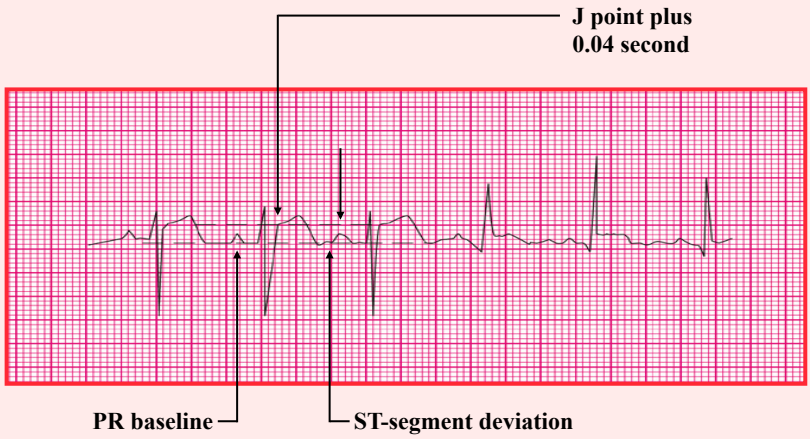

Let's evaluate the ECG

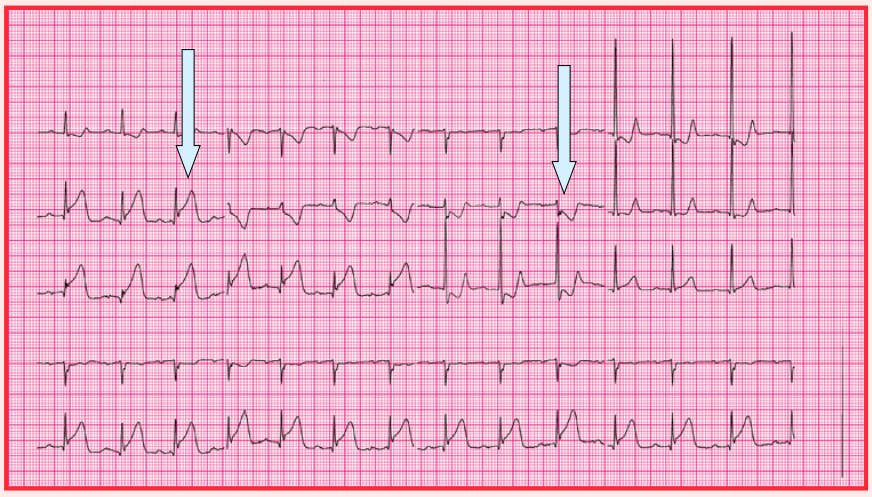

Inferior MI: Evaluate for RV Infarct

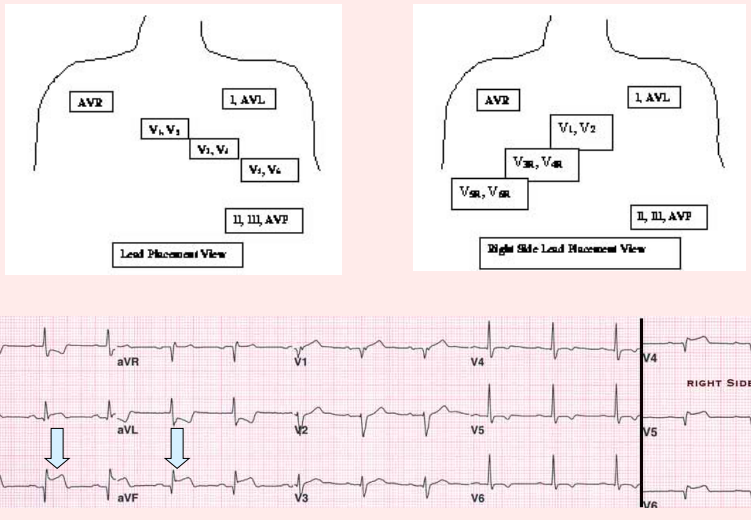

Clinical Significance of RV Infarct

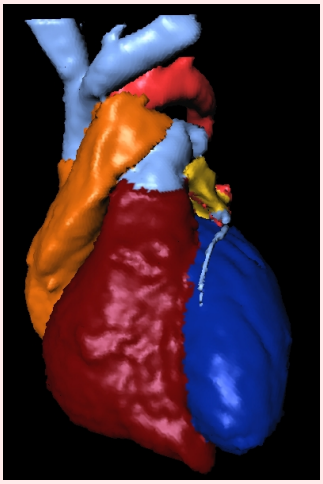

- Volume dependent
  - IV fluids
  - Avoid diuretics
- Excessive abnormal response to medications
  - Nitrates
  - Beta-blockers
  - Calcium channel blockers
- May also include inferiolateral wall of left ventricle

Management of Acute Coronary Syndromes *(Acute MI, Unstable angina)*

- Rest and recline
- Remember, Nurse MONA greets them
  - Morphine
  - Oxygen
  - Nitrates
  - Aspirin
- Cardiac monitor and 12 lead ECG, 18 leads if changes in II, III, or AVF
- IV access and blood draw for electrolytes, CPK enzymes, troponin I, beta natriuetic peptide (BNP)
  - Limit fluids if left heart involved
  - Avoid volume depletion if right heart involved
- Consider thrombolytics within 12 hours onset of chest pain
- Consider beta blockade with ischemia on ECG

Emergent Medications

- **Aspirin**
  - Immediate anti-platelet action
  - Easily reversed with transfusion
  - One adult aspirin (325 mg) chewed
- **Morphine**
  - Reduced sympathetic stimulation
  - Reduced preload (volume returning to heart)
  - Reduces pain
- **Nitrates**
  - Improved coronary perfusion
  - Reduces preload
- **Beta Blockers**
  - Reduces sympathetic stimulation
  - Decreases oxygen consumption
  - Minimizes infarct size
  - Metoprolol 5 mg IVP × 3, 5–15 minutes apart
  - Evaluate heart rate, blood pressure, breath sounds

ECG Abnormalities With Common Health Problems

Pulmonary embolism	Tachyarrhythmias, prominent P-waves, new right BBB
Hypokalemia	Slowed rate, U waves, PVCs
Hypocalcemia	Short PR interval, PVCs
Hypercalcemia	Bradycardia/junctional/heart block, prolonged PR interval
COPD	Large or biphasic P-waves, right BBB
Heart failure	Low voltage, nonspecific ST changes
Pericarditis/ effusion	Low voltage, precordial lead ST elevation

Myocarditis/Pericarditis

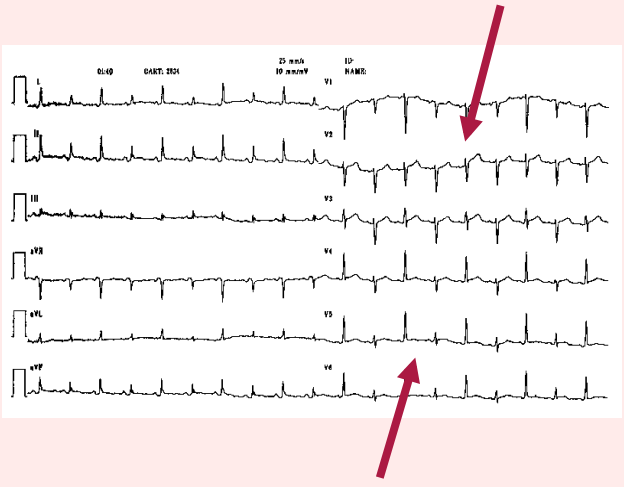

- Capillary permeability fluid extravasation
- Peak onset late, with large volume fluid overload
- Symptoms vague, easily missed
  - Dyspnea
  - Chest discomfort
  - Fatigue
  - Dysrhythmias
  - Troponin elevation
  - Precordial lead ST elevation