The Lite Version of 12-Lead ECG for Oncology APs

Brenda K. Shelton, DNP, RN, CCRN, AOCN®
Clinical Nurse Specialist
Sidney Kimmel Comprehensive Cancer Center at Johns Hopkins

Many thanks for sample ECGs and slide content provided with permission from Marida Twilley RN, MSN, and Paula Murray RN, MSN, Johns Hopkins Hospital Department of Medical Nursing

Disclosure

- Dr. Shelton has nothing to disclose.

Learning Objectives

- Recognize normal and abnormal EKG findings.
- Discuss the clinical implications of common EKG findings relative to the cancer patient, including drug or patient specific abnormalities.
- Discuss and compare small group reviews of provided EKG examples facilitated by faculty to identify patient abnormalities

Course Overview

- Review all the components of the 12-lead electrocardiogram.
- Interpret abnormal 12-lead electrocardiograms.
- Analyze the clinical implications of changes in the 12-lead electrocardiogram in the context of clinical case studies.

Overview of Cardiac Diagnostic Tests

ECG (12 lead, stress)	**Pictorial view of conduction pathways**	**Detect ischemia, injury, old infarction, electrolyte disorders, pericardial effusion**
Cardiac enzymes (CPK, Troponin)	Levels of enzymes leaking from myocytes at time of injury	Detection of current acute coronary syndrome.
Echocardiogram	Ultrasound of wall thickness, internal diameter, wall motion, and fluid in pericardial space.	Detects valve, global wall motion, and pericardial fluid abnormalities. Can calculate approximate EF.
MUGA scan	Accurate reflection of circulation of nuclear substance that detects coronary blood flow with/ without exercise. Wall motion abnormalities w/o uptake indicates old infarction.	Detection of significant compromise of coronary blood flow. Helpful to monitor progression of CAD, or recovery from MI.
Brain natriuretic peptide (BNP) serum level	Substance produced by a ventricle in failure. Normal serum < 100 mg/dl, clinically significant if > 300 mg/dl.	Early screening for heart failure, or monitoring response to heart failure treatment

Cardiac Conduction Pathways

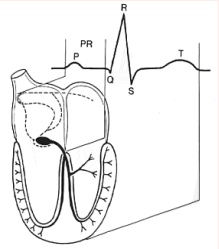

- Intrinsic pacemaker of the heart is the SA node, firing 60-100 times/ min
- Electrical conduction follows an efficient predetermined pathway, reflected as an ECG waveform
- End result of electrical conduction (depolarization) is muscular contraction and blood ejection
- Abnormalities in electrical conduction also affect pumping ability

Question #1

The major advantage of a 12-lead ECG over a basic rhythm strip is:

A. Ability to detect drug effects

B. Accuracy of rhythm interpretation

C. Having multiple views of cardiac conduction for broader diagnostic potential

D. Sensitivity to detect primary heart disorders

ECGs provide "photograph of electrical activity"

Rhythm strip

- Basic cardiac rates and rhythms
- Can be measured using 3 , 5, or 6 leads
- Usually a single dimensional view
- Best leads for visibility of all waves and measurement of waves/ intervals- II, III, V2, V3

12 Lead ECG

- Helpful to detect complex problems with conduction and heart function (e.g. bundle branch blocks, ischemia/ infarction, electrolyte abnormalities)
- Requires placement of 4 limb leads and 6 precordial leads
- Multidimensional- 12 views

ECG Paper

Height is "muscle mass"- Larger muscle mass = taller waves

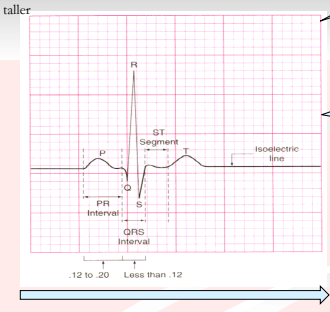

Each small box = 0.04 seconds

Each large box (5 small boxes) = 0.20 seconds

Width is "time"- Wider waves relates to longer time

The Isoelectric Form

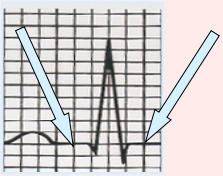

If there is no current detected or if the current is perpendicular to the lead , there will be **no** deflection on the ECG tracing.

Normal Components of an ECG

VOLTAGE in ml VOLTS.

(size of muscle mass to pass current through)

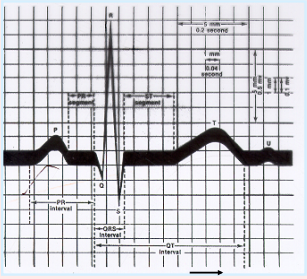

TIME IN SECONDS *(time it takes to move current through the muscle) Each small box = 0.04 sec*

Each ECG wave represents a different area of depolarization in the heart.

Assessment of the Heart Rhythm

- Calculate the heart rate- count number of complete complexes (P-QRS-T) within the 6 second strip and multiply X 10 (60 seconds). If missing components, count R waves (ventricular rate) separately from P waves (atrial rate).
- Assess regularity of R-R interval
- Look for P waves before EACH QRS. Are they "married to each other"? If intermittently present, mark.
- Assess PR interval in EACH complex, observing for variations in P waves, or length of interval. Normal is 0.12-0.20 sec [3-5 small boxes].
- Assess QRS interval in several complexes, noting if any are greatly at variance to the routine. Normal is 0.04- 0.10 sec [1-2.5 small boxes].
- Determine "key features" abnormality that aids in diagnosis of rhythm.

Overview of Dysrhythmias

Rate abnormality	Sinus rhythms (rate varies)	Normal sinus, sinus bradycardia, sinus tachycardia
P wave abnormality (atrial depolarization)	Atrial rhythms (rate varies)	Atrial fibrillation, Atrial flutter, Atrial tachycardia
Displaced location of P wave/ absent P wave with normal QRS (junction/ nodal transmission)	Junctional/ Nodal rhythms (slow rate)	Juntional rhythm, Accelerated junctional rhythm
QRS abnormality (ventricular depolarization)	Ventricular rhythms (rate fast or absent)	Ventricular tachycardia, Ventricular fibrillation
Abnormal P-QRS relationship; more P waves than QRS (current transmission between atria and ventricles)	Heart blocks (slow rate)	First degree Second degree type I, Second degree Type II, Third degree

Question #2

The ECG lead where all waves are expected to be inverted is:

A. Lead I

B. Lead AVR

C. Lead AVF

D. Lead V1

E. Lead V6

12-Lead ECG: Conceptual Tenets

- Core concepts of "multilead ECGs"
  - Taking pictures of heart's conduction from multiple angles
  - Each lead represents a different "view"
  - Each lead is oriented to a section of the heart
- What information is provided through its evaluation
  - Anatomical orientation of the heart
  - Size of the chambers
  - Disturbance of conduction
  - Ischemia, injury or infarction
  - Electrolyte imbalance
  - Drug toxicity/therapy
- Process of evaluation
  - Assess ECG rhythm via rate, regularity, PR, QRS, QT
  - Assess other medical/ cardiac problems through analysis of the 12 leads
  - Review each lead for the defined parameters
  - Check for upright waveforms in all except AVR where ALL waveforms are inverted. If AVR is not inverted check lead placement. Note inverted waves and lead locations.
  - Check R wave progression in precordial (chest) leads
  - Assess each lead for significant Q waves, ST elevation or depression, T wave inversion

Question #3

How is normal R wave progression defined?

A. R waves that descend in height between V1 and V6

B. R waves that increase in height between V1 and V6

C. R waves in the V leads that progress from above the isoelectric line, then become more equal (half above and half below), then below the isoelectric line*

D. R waves that are primarily negative in AVR, AVL, and AVF

Precordial Leads

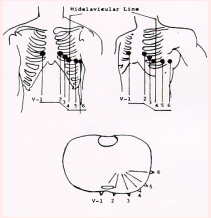

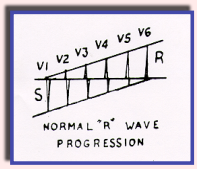

- V1 and V2 - Right-sided or Septal Leads
- V3 and V4 - Transitional Leads
- V5 and V6- Left-sided or Lateral Leads

Precordial Leads:
R Wave Progression

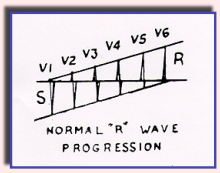

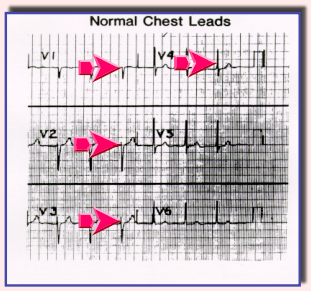

Rate:_____ P wave:_____ Axis: Lead I:_____
Rhythm:_____ Sig Q wave:_____ AVF:_____
PR Interval:_____ ST Seg:_____ Equiphasic Limb Lead_____
QRS Interval_____ T wave:_____ Axis: _____
QT Interval: _____ INTERPRETATION:_____

1. Check for P, QRS, T waves all leads
2. Check for upright waves all except AVR
3. Check ST segments
4. Check Q waves
5. R wave progression

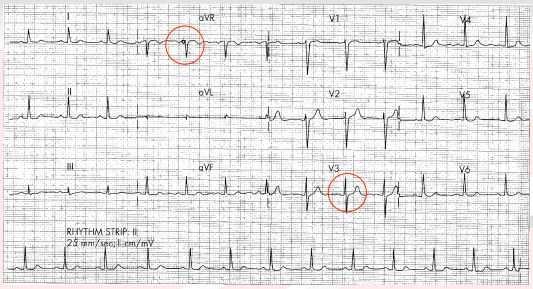

Coronary Artery Disease

- **Risk factors**
  - Older age
  - Chest irradiation including the heart
  - Heavily treated with alkylating agents
  - Long-term corticosteroids
  - Progranulocytic leukemia
  - Link between cancers and CV disease
  - Higher incidence of acute myocardial infarction with certain malignancies
  - Einhorn regimen for testicular cancer
  - Bevaizumab
- **Onset as early as 2 years after exposure**
- **Peak incidence 10 years after exposure**

Cardiac Disease: Case Study

- 42-year-old man
- S/P total gastrectomy and esophageal pull-up for gastric carcinoma 1 year ago after presentation for small bowel obstruction
- New metastases to the liver
- Presenting for new treatment evaluation
- Chest pain, nausea, dizziness, diaphoresis
- Vital signs: T 35.9, HR 54, R 38, BP 94/60, O_2 sat 88%
- Diffuse abdominal tenderness without rebound signs



Case Study: Further Evaluation

- Immediate rest, recline
- Oxygen therapy 2L/min
- 12 lead ECG, followed by continuous monitoring
- IV start, KVO normal saline
- Labs: hematology, chemistry, LFTs, coagulation, type and crossmatch, cardiac enzymes with troponin I
- Determine level of suspicion for cardiovascular disease:
  - Other physical problems that could mimic cardiac disease?
  - Patient's past medical history
  - Chest pain characteristics
  - Careful evaluation of 12 lead ECG

Question #4

12-lead ECG changes indicative of acute myocardial injury include:

A. Inverted T waves

B. ST depression

C. ST elevation

D. Q waves in at least 2 leads

E. High-voltage QRSs in a lead

Myocardial Infarction

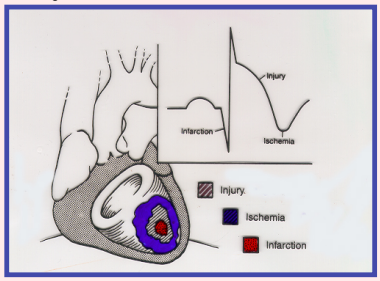

Three ways the myocardial tissue is affected:

Significant Q-Waves

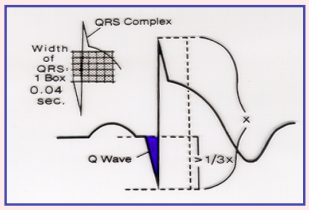

A <u>SIGNIFICANT</u> Q-wave should be:

1. One-third height of QRS complex.
2. 0.04 second (one small box wide) in duration.
3. Must be present in two related leads.

More on Q-Waves….

1. Q-waves are not significant if seen in one lead.
2. Q-waves are never significant in AVR.
3. Q-waves in V1 <u>alone</u> are ignored.
4. Q-waves in III <u>alone</u> are ignored.

Ventricular Repolarization: ST Segment

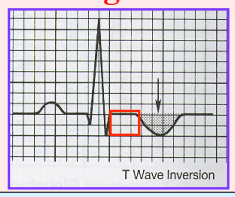

- **The ST-segment is normally isoelectric**
- **Sensitive indicator of myocardial oxygenation**
- **May be elevated or depressed secondary to variations in MVO_2**

Ventricular Repolarization:
(J Point)

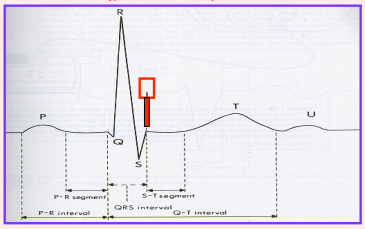

- **Point at which the QRS wave meets the isoelectric baseline**
- **Used as a reference point in determining ST changes**
- **Measure the elevation or depression .04 to .08 seconds after the J point**

12-Lead ECG Variations in AMI and Angina

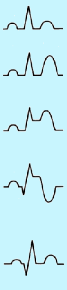

Baseline

Ischemia—tall or inverted T wave (infarct), ST segment may be depressed (angina)

Injury—elevated ST segment, T wave may invert

Infarction (Acute)—abnormal Q wave, ST segment may be elevated and T wave may be inverted

Infarction (Age Unknown)—abnormal Q wave, ST segment and T wave returned to normal

Question #5

A patient having ST depression in leads II and III and inverted T waves in AVF has:

A. New anterior myocardial infarction

B. Old anterior myocardial infarction

B. Anterior ischemia

C. New inferior myocardial infarction

D. Old inferior infarction

E. Inferior ischemia

AMI Localization

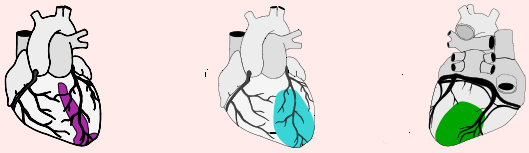

I lateral	aVR	V_1 septal	V_4 anterior
II inferior	aVL lateral	V_2 septal	V_5 lateral
III inferior	aVF inferior	V_3 anterior	V_6 lateral

Recognition of AMI

- Know what to look for
  - ST elevation >1 mm
  - 3 contiguous leads
- Know where to look
  - Refer to *2005 ECC Handbook*

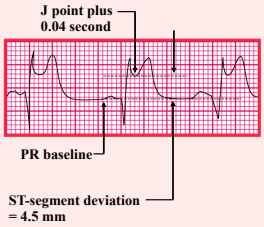

How to Measure ST-Segment Deviation

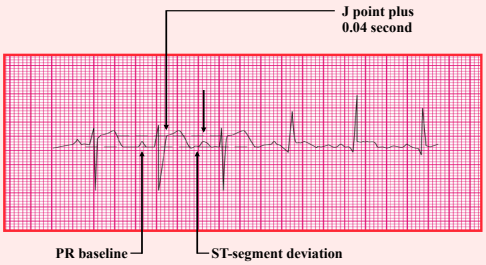

Let's evaluate the ECG

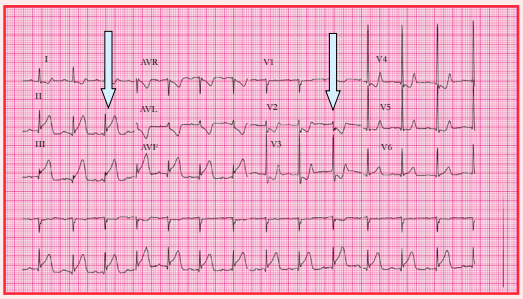

ST elevation: II, III, AVF; ST depression I, AVL, V2, V3, V4; Flat T wave V1

Reciprocal Changes

- ST depression in leads opposite of those with ST elevation is considered to be reciprocal changes rather than ischemia.

Site	Facing	Reciprocal
Septal	V1 (some V2 overlap)	V 7, V8, V9
Anterior	V2, V3, V4	None
Lateral	I, AVL, V5, V6	II, III, AVF
Inferior	II, III, AVF	I, AVL

ARS Question #6

A 12-lead ECG can be performed on the right side of the chest to detect certain right ventricular abnormalities.

A. True

B. False

Inferior MI: Evaluate for RV Infarct

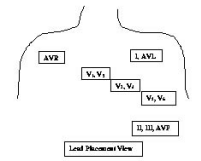

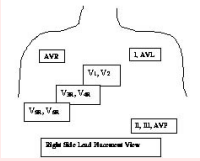

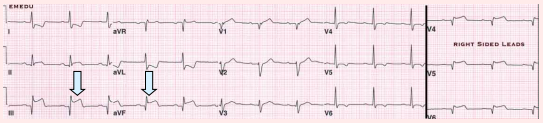

Clinical Significance of RV Infarct

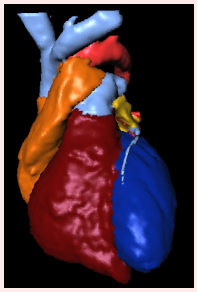

- Volume dependent
  - IV fluids
  - Avoid diuretics
- Excessive abnormal response to medications
  - Nitrates
  - Beta blockers
  - Calcium channel blockers
- May also include inferio-lateral wall of left ventricle

Management of Acute Coronary Syndromes *(Acute MI, Unstable angina)*

- Rest and recline
- Remember Nurse MONA greets them
  - Morphine
  - Oxygen
  - Nitrates
  - Aspirin
- Cardiac monitor and 12 lead ECG, 18 leads if changes in II, III, or AVF
- IV access and blood draw for electrolytes, CPK enzymes, troponin I, beta natriuetic peptide (BNP)
  - Limit fluids if left heart involved
  - Avoid volume depletion if right heart involved
- Consider thrombolytics: within 12 hours onset of chest pain
- Consider beta blockade with ischemia on ECG

Emergent Medications

- **Aspirin**
  - Immediate anti-platelet action
  - Easily reversed with transfusion
  - One adult aspirin (325 mg) chewed
- **Morphine**
  - Reduced sympathetic stimulation
  - Reduced preload (volume returning to heart)
  - Reduces pain
- **Nitrates**
  - Improved coronary perfusion
  - Reduces preload
- **Beta Blockers**
  - Reduces sympathetic stimulation
  - Decreases oxygen consumption
  - Minimizes infarct size
  - Metoprolol 5 mg IVP x 3, 5–15 minutes apart
  - Evaluate heart rate, blood pressure, breath sounds

Case Study Follow-up

- 12 lead ECG showed injury (ST elevation) in leads II, III, AVF; ischemia (inverted T waves) in leads I, V6
- CPK mildly elevated, but without troponin elevation
- Chest x-ray and chest CT scans inconclusive
- Echocardiogram showed normal wall motion, absence of pericardial fluid, and reduced ejection fraction (38%)
- Presumed esophageal spasm with concomitant cardiac ischemia

Practice ECGs

ECG # 18

Rate:_____ P wave:_____ Axis: Lead I:_____
Rhythm:_____ Sig Q wave:_____ AVF:_____
PR Interval:_____ ST Seg:_____ Equiphasic Limb Lead_____
QRS Interval_____ T wave:_____ Axis: _____
QT Interval: _____ INTERPRETATION:_____

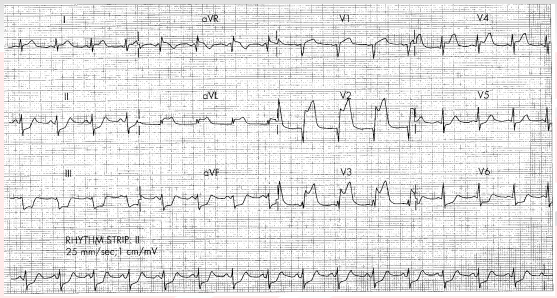

ECG #10

Rate:_____ P wave:_____ Axis: Lead I:_____
Rhythm:_____ Sig Q wave:_____ AVF:_____
PR Interval:_____ ST Seg:_____ Equiphasic Limb Lead_____
QRS Interval_____ T wave:_____ Axis: _____
QT Interval: _____ INTERPRETATION:_____

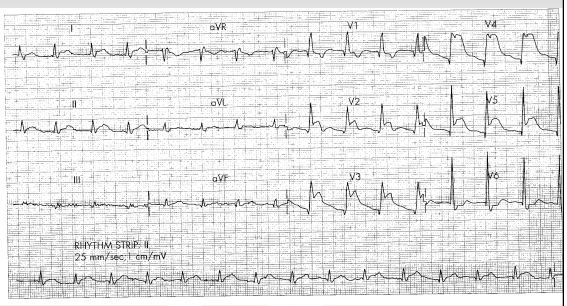

ECG #12

Rate:_____ P wave:_____ Axis: Lead I:_____
Rhythm:_____ Sig Q wave:_____ AVF:_____
PR Interval:_____ ST Seg:_____ Equiphasic Limb Lead_____
QRS Interval_____ T wave:_____ Axis: _____
QT Interval: _____ INTERPRETATION:_____

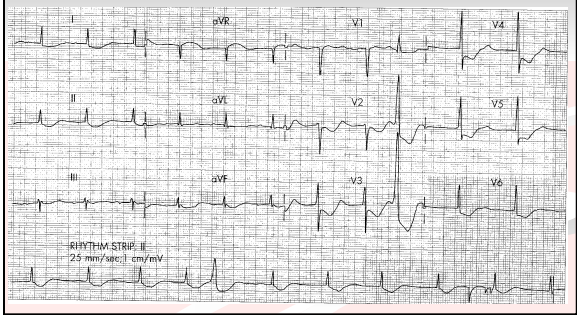

Rate:_____ P wave:_____ Axis: Lead I:_____
Rhythm:_____ Sig Q wave:_____ AVF:_____
PR Interval:_____ ST Seg:_____ Equiphasic Limb Lead_____
QRS Interval_____ T wave:_____ Axis: _____
QT Interval: _____ INTERPRETATION:_____

ECG # 14

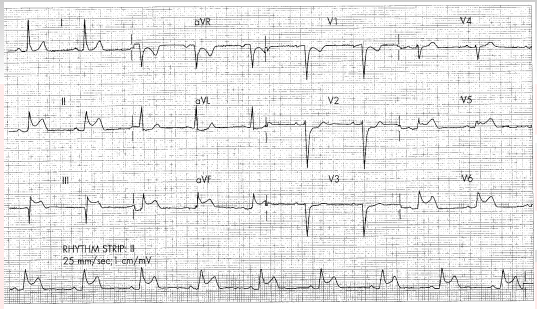

Figure 5-34
Resting 12-Lead ECG

Rate:_____ P wave:_____ Axis: Lead I:_____
Rhythm:_____ Sig Q wave:_____ AVF:_____
PR Interval:_____ ST Seg:_____ Equiphasic Limb Lead_____
QRS Interval_____ T wave:_____ Axis: _____
QT Interval: _____ INTERPRETATION:_____

ECG # 18

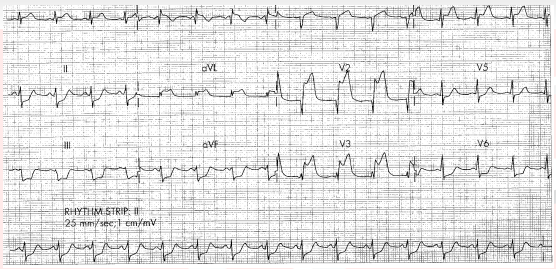

Question #7

What do tall R waves in lead V1 and V2 indicate?

A. Acute myocardial injury
B. Conduction disturbance
C. Atrial hypertrophy
D. Right bundle branch block
E. Left bundle branch block

Blocks Ahead . . .

Bundle Branch System

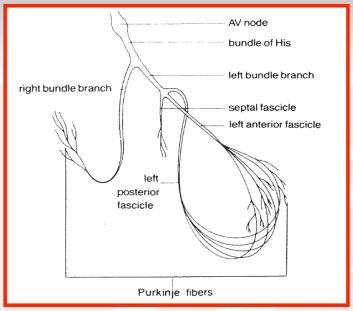

Bundle Branch System

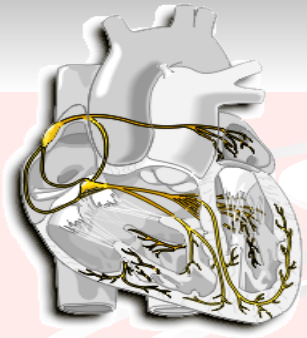

Criteria for Bundle Branch Block

- Must have a supraventricular origin
- Must have a QRS $\geq$ 0.12

Right Bundle Branch Block

RBBB Criteria
(Check QRS 1st)

- Look in V_1 & V_2
  - R,R' wave!
- Look in V_5, V_6, & Lead I
  - "slurred S wave"

V_6 Lead I

V1 - 2

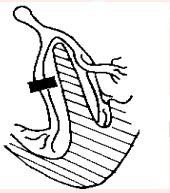

Right BBB

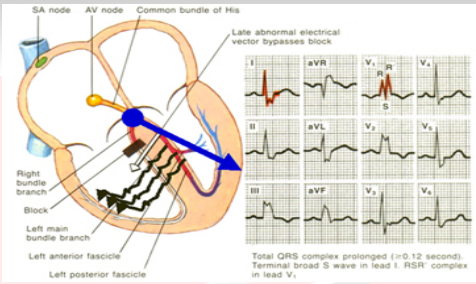

Left Bundle Branch Block

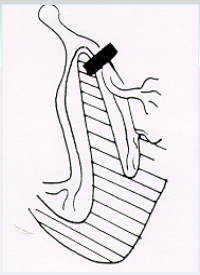

LBBB Criteria
(Check QRS 1st)

- Look in V_5, V_6, or Lead I
- 'blunted' positive QRS
  - T wave inverted
- Look in V_1-V_3
  - predominately negative QRS



Left BBB

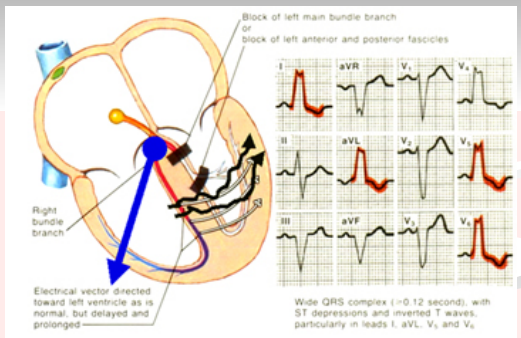

ECG # 20

Rate:_____ P wave:_____ Axis: Lead I:_____
Rhythm:_____ Sig Q wave:_____ AVF:_____
PR Interval:_____ ST Seg:_____ Equiphasic Limb Lead_____
QRS Interval_____ T wave:_____ Axis: _____
QT Interval: _____ INTERPRETATION:_____

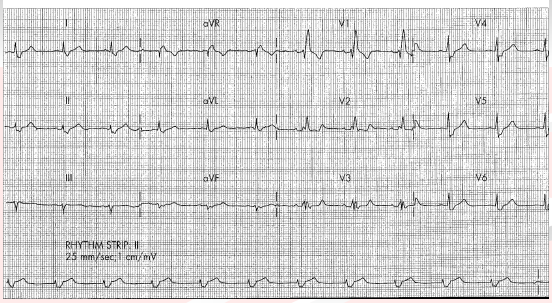

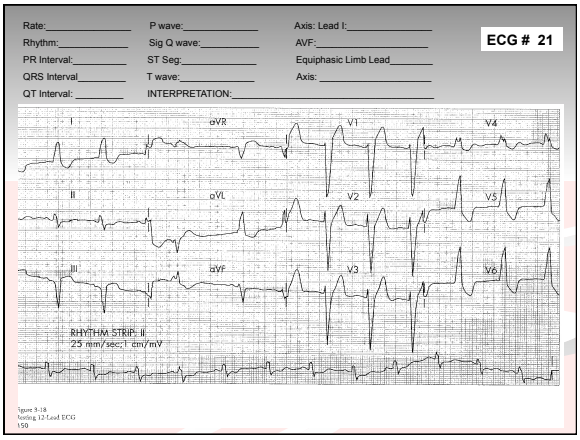

ECG Abnormalities with Common Health Problems

Pulmonary embolism	Tachyarrhythmias, Prominent P waves, New Right BBB
Hypokalemia	Slowed rate, U waves, PVCs
Hypocalcemia	Short PR interval, PVCs
Hypercalcemia	Bradycardia/ Junctional/ Heart block, prolonged PR interval
COPD	Large or biphasic P waves, Right BBB
Heart failure	Low voltage, nonspecific ST changes
Pericarditis/ effusion	Low voltage, precordial lead ST elevation

Myocarditis/ Pericarditis

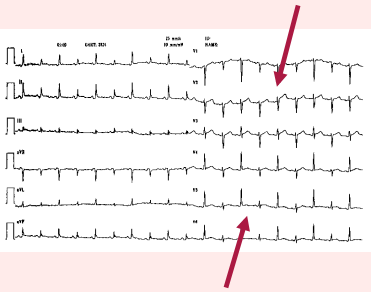

- Capillary permeability fluid extravasation
- Peak onset late, with large volume fluid overload
- Symptoms vague, easily missed
  - Dyspnea
  - Chest discomfort
  - Fatigue
  - Dysrhythmias
  - Troponin elevation
  - Precordial lead ST elevation

You are evaluating a patient with glioblastoma multiforme 20 weeks after partial resection, receiving radiation therapy and temozolomide who presented to outpatient clinic with dyspnea on exertion, fatigue and new onset tachycardia.

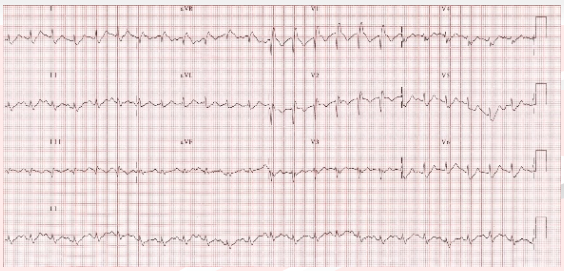

You admit a patient from home with a three-day history of vomiting and no urinary output for 24 hours.
You obtain an admission ECG.

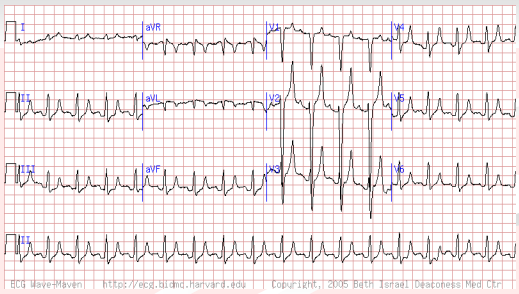

Your patient is delirious and agitated after a 21-day admission for leukemia consolidation. The resident orders Haldol 3 mg IV every 6 hours prn. The patient has not had an ECG since admission; so you obtain one.

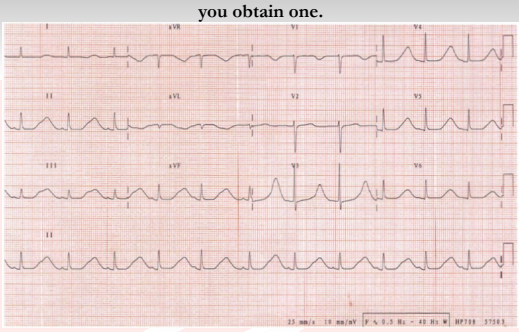

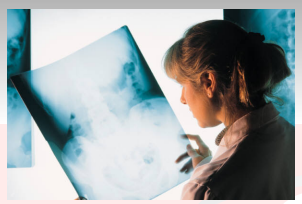

I hear and I…. Imagine.
I see and I …. Understand.
I do and I…. Remember.